

SUB HEPATIC POSITION OF THE VERMIFORM APPENDIX WITH ADHESION - A CASE FINDING

Dr. Anju Choudhary, Pooja Garg and Dr. Surajit Ghatak

Department of Anatomy, All India Institute of Medical Sciences, Jodhpur, India

ABSTRACT: *The vermiform appendix is the most variable abdominal organ in term of position, extent and relations. The location of appendix is important when it comes to clinical presentation of a patient with appendicitis. Variation in the appendix with adhesion was noted in 55 years old male cadaver during regular dissection classes of undergraduates. Sub-hepatic position of appendix might congest the sub-hepatic region and minimize the intestinal movements. The knowledge of its variations in position is important because in appendicitis it may create iatrogenic complications.*

KEYWORDS: Appendicitis, Cadaver, Sub hepatic, Vermiform Appendix.

INTRODUCTION

Intestinal congenital anomalies are most common abnormalities, these are gut rotation, non-rotation or malrotation. In terms of position extent peritoneal and visceral relations appendix is the most common variable organ.^{1,2} The knowledge of its variations in position is important because in appendicitis it may create iatrogenic complications.³

The variable anatomy of the appendix may cause complication during appendectomy. It may prolong the operating time or can affect the cosmetic outcome because it may require extension of incision or additional muscle splitting.⁴

Case Report

During routine dissection of abdomen of abdomen in a male cadaver aged approximately 55 years fixed in 10% formalin, with first year undergraduate medical students in the department of Anatomy we observed abnormal position of appendix and caecum in sub hepatic region below the right hepatic lobe, whereas the right iliac fossa was observed empty.

The tip of appendix was directed towards the gallbladder and it was suspended by mesoappendix below the liver. (Figure 1)

DISCUSSION

The subhepatic caecum and appendix are abnormalities of the third stage of rotation of midgut. It may cause because of abnormal growth of ascending colon or may be failure of migration of caecum to the iliac fossa.^{5,6}

Most cases of subhepatic appendix are asymptomatic and remain unnoticed but may cause surgical complications. As the appendix was situated near the gallbladder so the pain of appendicitis may mimic of acute coli cystitis and will be localized in the right upper quadrant.

This type of case may also be associated with the fixation of small intestine to the posterior abdominal wall and may cause volvulus of small intestine.⁷

Failure to identify these misplacements may lead to errors and detrimental prolongation of the operation.

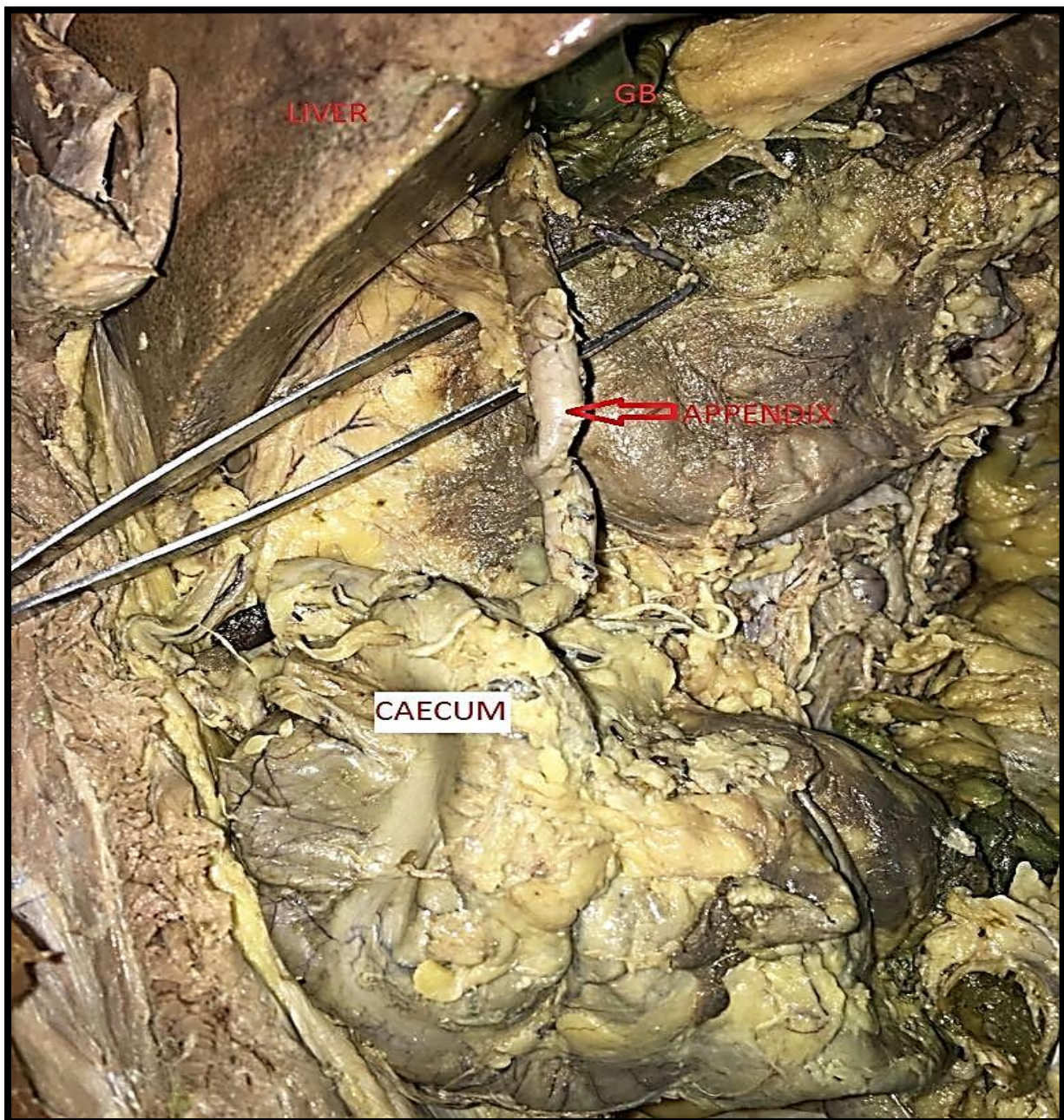


Fig. 1: Showing (Subhepatic Appendix and Caecum, Liver, Gallbladder)



CONCLUSION

It is concluded that the developmental mislocation of the portion of the midgut is enormously common. The presence of subhepatic caecum and appendix may be of surgical importance which may lead to diagnostic delay. Hence surgeons should be aware of these types of variation to avoid unfamiliar complications.

In the current case we found caecum and appendix were lie near the liver (subhepatic position). The knowledge of this type of variations may be useful for the radiologist and surgeons.

REFERENCES

- [1] J.Deli'c,A.Savkovi'c, and E. Isakovi'c, (2002). "Variation in the position and point of origin of vermiform appendix," Medicinski Arhiv,vol.56,no.1,pp.5-8.
- [2] I. Ahmed, K.S. Asgeirsson, I.J. Beckingham, and D.N. Lobo (2007). "The position of the vermiform appendix at laparoscopy." Surgical and Radiological Anatomy,Vol. 29, no.2, pp. 165-168.
- [3] S.B. Nayak, B.M.George, S. Mishra S. Surendran, P. Shetty, and S.D. Shetty (2013). "Sessile ileum, subhepatic cecum and uncinat appendix that might lead a diagnostic dilemma," Anatomy & Cell Biology, vol.46, no.4, pp.296-298.
- [4] V.Narayan singh, M.J. Ramdas, J. Singh, R Singh-Rampaul, and D Maharaj (2003). "McBurney's point : are we missing it?"Surgical and Radiologic Anatomy, vol.24, no. 6,pp. 363-365.
- [5] Moore KL, Persaud TVN (2008) The developing Human clinical oriented embryology. 8th ed. New Delhi: The Elsevier; p.218.
- [6] Clarence E, Gardner E, Jr. (1950). The surgical significance of Anomalies in Intestinal Rotation. Ann Surg. 131(6):879-96.
- [7] Nagashree MV, Gireesh, Subhash LP, PaiV. (2013). Journal of Clinical and Diagnostic Research. 7(9):1992-3.